

## Chapter 2

# Attitudinally Correct Cardiac Anatomy

Alexander J. Hill

**Abstract** Anatomy is one of the oldest branches of medicine. Throughout time, the discipline has been served well by a universal system for describing structures based on the “anatomic position.” Unfortunately, cardiac anatomy has been a detractor from this long-standing tradition, and has been incorrectly described using confusing and inappropriate nomenclature. This is most likely due to the examination of the heart in the “valentine position,” in which the heart stands on its apex as opposed to how it is actually oriented in the body. The description of the major coronary arteries, such as the “anterior descending” and “posterior descending,” is attitudinally incorrect; as the heart is oriented in the body, the surfaces are actually superior and inferior. An overview of attitudinally correct human anatomy, the problem areas, and the comparative aspects of attitudinally correct anatomy will be presented in this chapter.

**Keywords** Cardiac anatomy · Attitudinally correct nomenclature · Comparative anatomy

### 2.1 Introduction

Anatomy is one of the oldest branches of medicine, with historical records dating back at least as far as the 3rd century BC. Cardiac anatomy has been a continually explored topic throughout this time, and there are still publications on new facets of cardiac anatomy being researched and reported today. One of the fundamental tenets of the study of anatomy has been the description of the structure based on the universal orientation, otherwise termed the “anatomic position” which depicts the subject facing the observer, and is then

divided into three orthogonal planes (Fig. 2.1). Each plane divides the body or individual structure within the body (such as the heart) into two portions. Thus, using all three planes, each portion of the anatomy can be localized precisely within the body. These three planes are called: (1) the *sagittal* plane, which divides the body into right and left portions; (2) the *coronal* plane, which divides the body into anterior and posterior portions; and (3) the *transverse* plane, which divides the body into superior and inferior portions. Each plane can then be viewed as a slice through a body or organ and will also have specific terms that can be used to define the structures within. If one is looking at a sagittal cut through a body, the observer would be able to describe structures as being anterior or posterior and superior or inferior. On a coronal cut, the structures would be able to be described as superior or inferior and right or left. Finally, on a transverse cut, anterior or posterior and right or left would be used to describe the structures. This terminology should be used regardless of the actual position of the body. For example, assume an observer is looking down at a table and does not move. If a body is lying on its back on this table, the anterior surface would be facing upwards toward the observer. Now, if the body is lying on its left side, the right surface of the body would be facing upwards toward the observer, and the anterior surface would be facing toward the right. Regardless of how the body is moved, the orthogonal planes used to describe it move with the body and do not stay fixed in space. The use of this position and universal terms to describe structure have served anatomists well and have led to easier discussion and translation of findings amongst different investigators.

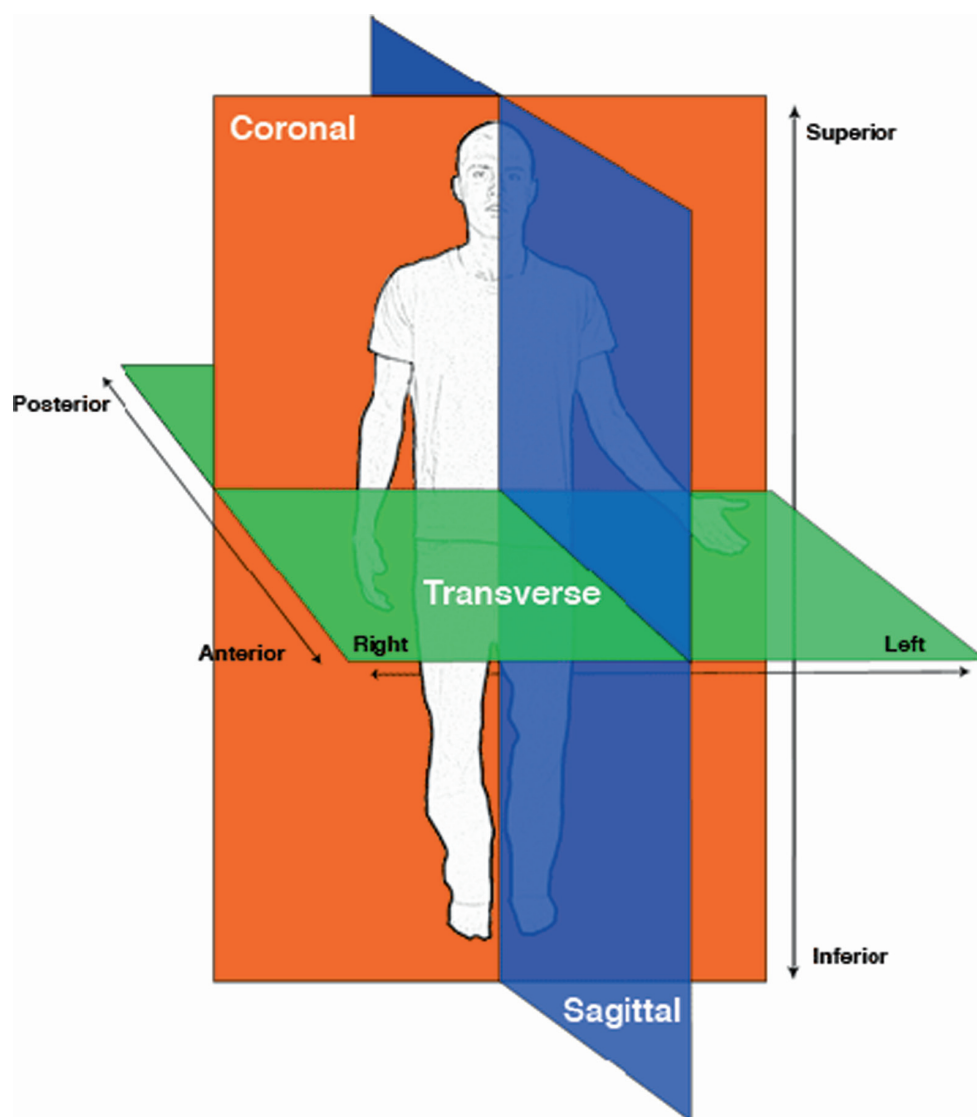
### 2.2 The Problem: Cardiac Anatomy Does Not Play by the Rules

As described above, the use of the “anatomic position” has stood the test of time and is still used to describe the position of structures within the body. However, within

---

A.J. Hill (✉)  
University of Minnesota, Departments of Biomedical Engineering  
and Surgery, and Medtronic, Inc.,  
8200 Coral Sea St. NE, MVS84, Mounds View, MN 55112, USA  
e-mail: alex.hill@medtronic.com

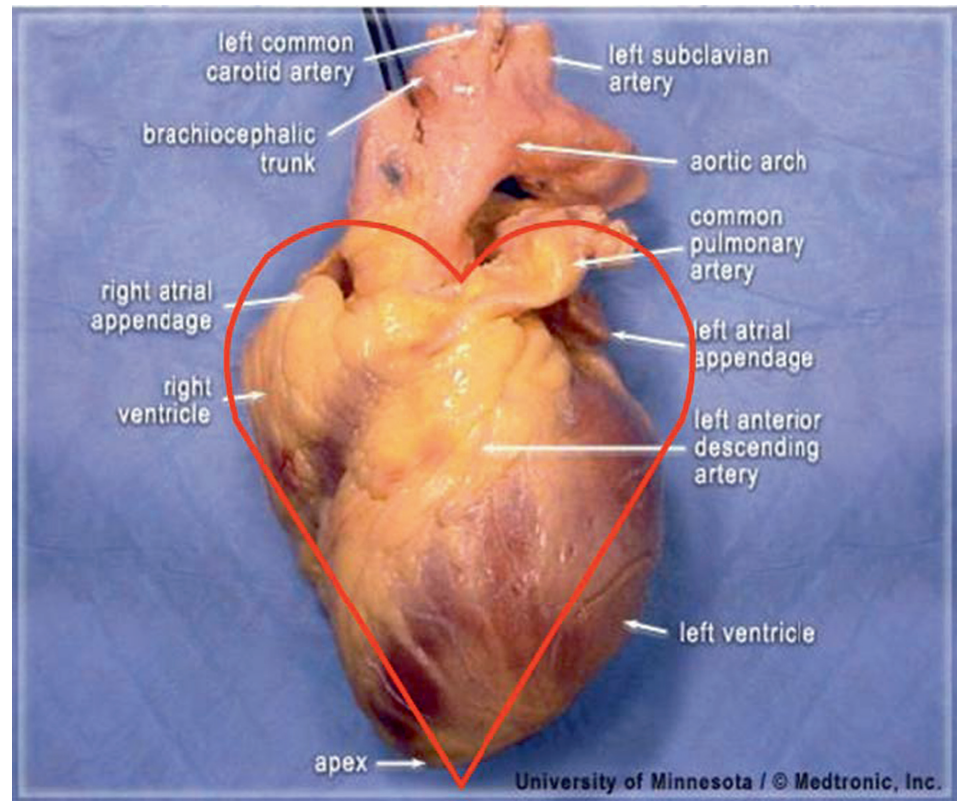
**Fig. 2.1** Illustration showing the anatomic position. Regardless of the position of the body or organ upon examination, the anatomy of an organ or the whole should be described as if observed from this vantage point. The anatomic position can be divided by three separate orthogonal planes: (1) the sagittal plane, which divides the body into right and left portions; (2) the coronal plane, which divides the body into anterior and posterior portions; and (3) the transverse plane, which divides the body into superior and inferior portions



approximately the last 50 years, descriptions of cardiac anatomy have not adhered to the proper use of these terms, and rather have been replaced with inappropriate descriptors. There are two major reasons for this: (1) many descriptions of heart anatomy have been done with the heart removed from the body and incorrectly positioned during examination and (2) a “heart-centric” orientation has been preferred to describe the structures. These two reasons are interrelated and negatively affect the proper description of cardiac anatomy. Typically, when the heart is examined outside the body it has been placed on its apex into the so-called “valentine position,” which causes the heart to appear similar to the common illustration of the heart used routinely in everything from greeting cards to instant messenger

icons (Fig. 2.2). It is this author’s opinion that this problem has been confounded by the comparative positional differences seen between humans and large mammalian cardiac models used to help understand human cardiac anatomy and physiology. As you will see in the following sections, the position of the heart within a sheep thorax is very similar to the valentine position used to examine human hearts. I will point out that I have been guilty of describing structures in such a manner, as is evidenced by some of the images available in the Visible Heart<sup>®</sup> Viewer CD (Fig. 2.2), as have countless others as seen in the scientific literature and many textbooks (even including this one). Regardless, it is a practice I have since given up and have reverted to the time-honored method using the “anatomic position.”

**Fig. 2.2** A human heart viewed from the so-called anterior position, demonstrating the “valentine” heart orientation used by many to incorrectly describe anatomy. The red line surrounding the heart is the characteristic symbol, which was theoretically derived from observing the heart in the orientation



Further impacting the incorrect description of cardiac anatomy is the structure of the heart itself. A common practice in examining the heart is to cut the ventricular chambers in the short axis, which is perpendicular to the long axis of the heart which runs from the base to the apex. This practice is useful in the examination of the ventricular chambers, but the cut plane is typically confused as actually being transverse to the body when it is, in most cases, an oblique plane. The recent explosion of tomographic imaging techniques, such as magnetic resonance imaging (MRI) and computed tomography (CT), in which cuts such as the one just described are commonly made, have further fueled the confusion.

Nevertheless, this incorrect use of terminology to describe the heart can be considered to impact a large and diverse group of individuals. Practitioners of medicine, such as interventional cardiologists and electrophysiologists are affected, as are scientists investigating the heart and engineers designing medical devices. It is considered here that describing terms in a more consistent manner, and thus using the appropriate terminology, would greatly increase the efficiency of interactions between these groups.

It should be noted that there have been a few exceptions to this rule, in that attempts have been made to promote proper use of anatomic terminology. Most notable are the works of Professor Robert Anderson [1–4],

although he will also admit that he has been guilty of using incorrect terminology in the past. Other exceptions to this rule are Wallace McAlpine’s landmark cardiac anatomy textbook [5] and an excellent textbook by Walmsley and Watson [6].

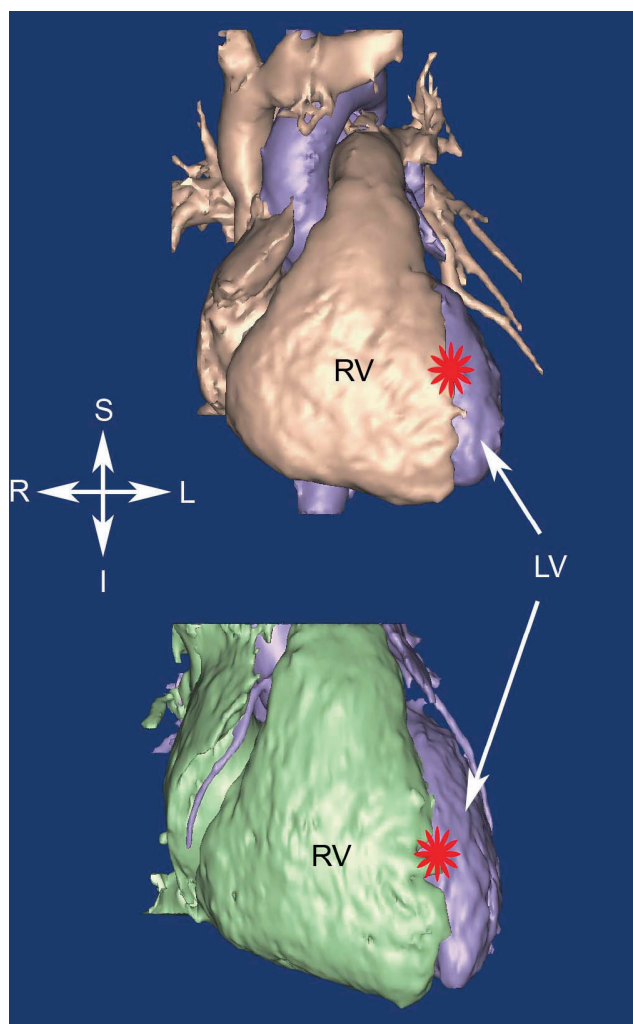
In addition to these exceptions, a small group of scientists and physicians has begun to correct the many misnomers that have been used to describe the heart in the recent past; this is the major goal of this chapter. A description of the correct position of the body within the heart will be presented as well as specific problem areas, such as the coronary arteries where terms such as left anterior descending artery are most obviously incorrect and misleading.

## 2.3 The Attitudinally Correct Position of the Human Heart

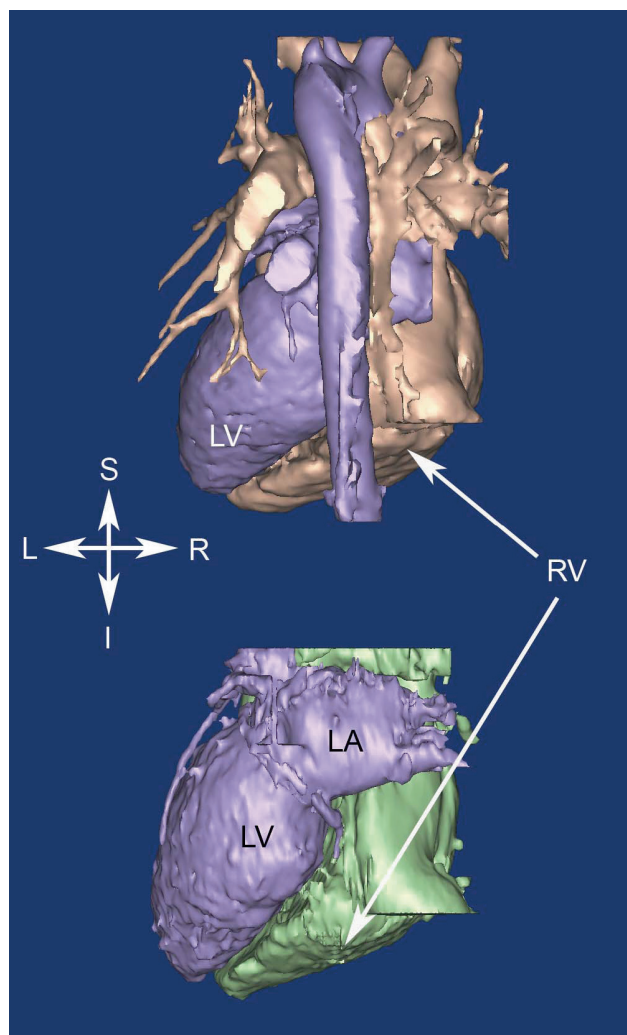
The following set of figures used to describe the correct position of the heart within the body was created from 3D volumetric reconstructions of magnetic resonance images of healthy humans with normal cardiac anatomy. In Fig. 2.3, the anterior surfaces of two human hearts are shown. Note that in this view of the heart, the major structures



visible are the right atrium and right ventricle. In reality, the right ventricle is positioned anteriorly and to the right of the left ventricle. Also, note that the apex of the heart is positioned to the left and is not inferior, as in the valentine position. Furthermore, note that the so-called anterior interventricular sulcus (shown with a red star), in fact, begins superiorly and travels to the left and only slightly anteriorly. Figure 2.4 shows the posterior surfaces of two human hearts, in which the first visible structure is the descending aorta. Anterior to that are the right and left atria. Figure 2.5 shows the inferior or diaphragmatic surfaces of two human hearts, commonly referred to as the posterior surface, based on valentine positioning. The

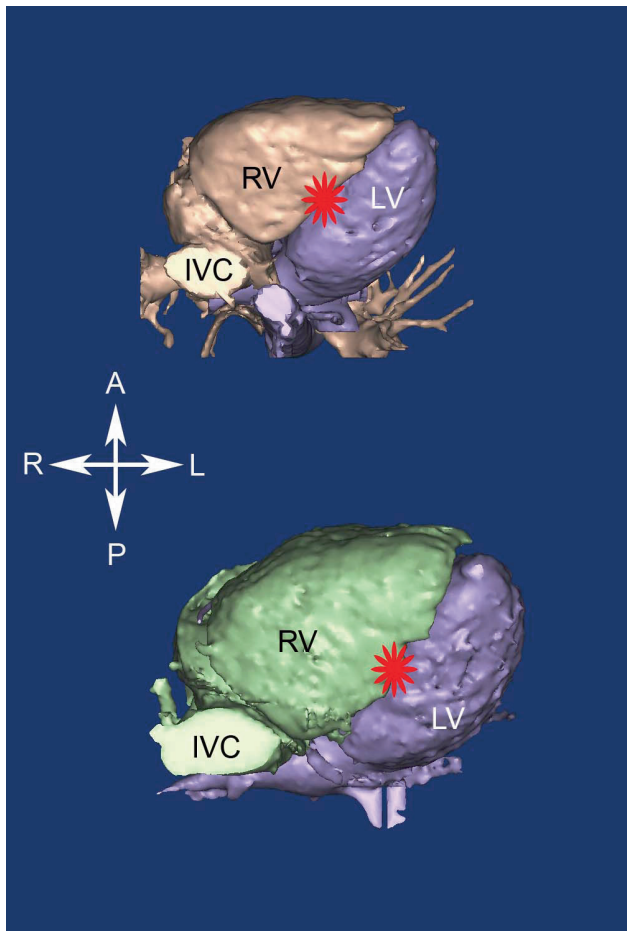


**Fig. 2.3** Volumetric reconstructions from magnetic resonance imaging showing the anterior surfaces of two human hearts. The major structures visible are the right atrium and right ventricle. The apex of the heart is positioned to the left and is not inferior as in the valentine position. The so-called anterior interventricular sulcus (shown with a red star) in fact begins superiorly and travels to the left and only slightly anteriorly. I, inferior; L, left; LV, left ventricle; R, right; RV, right ventricle; S, superior



**Fig. 2.4** Volumetric reconstructions from magnetic resonance imaging showing the posterior surfaces of two human hearts. The major structures visible are the right and left atrium and the descending aorta (*top image only*). The apex of the heart is positioned to the left and is not inferior as in the valentine position. I, inferior; L, left; LA, left atrium; LV, left ventricle; R, right; RV, right ventricle; S, superior

inferior caval vein and descending aorta are cut in the short axis; in this region of the thorax, they tend to travel parallel to the long axis of the body. Note that the so-called posterior interventricular sulcus is actually positioned inferiorly (shown with a red star). Figure 2.6 shows a superior view of two human hearts. In this view, the following structures are visible: (1) the superior caval vein; (2) aortic arch and the major arteries arising from it; (3) the free portion of the right atrial appendage; and (4) the pulmonary trunk which, after arising from the right ventricle, runs in the transverse plane before bifurcating into the right and left pulmonary arteries. Also, note that the position of the “anterior” interventricular



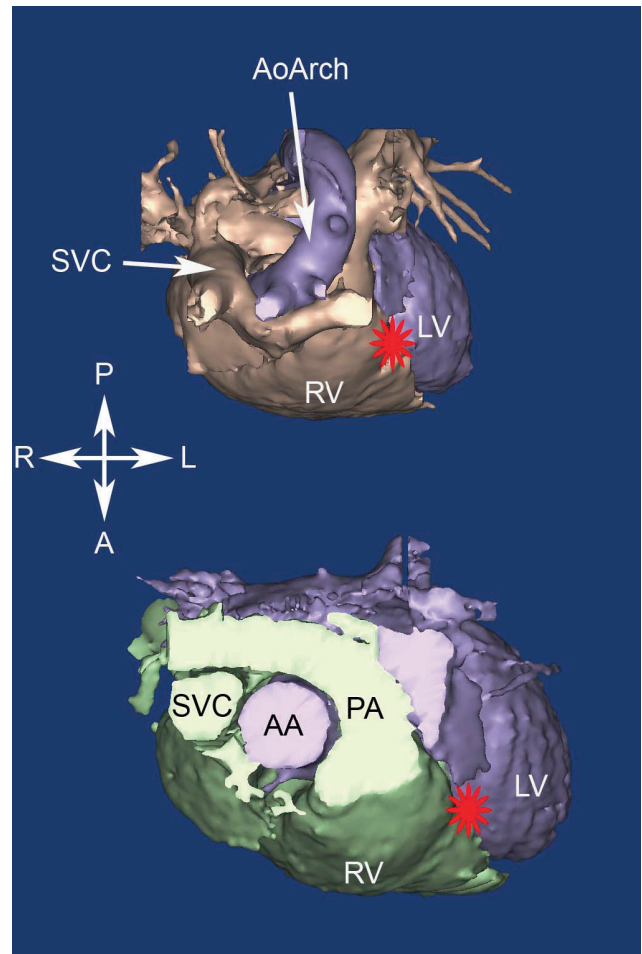
**Fig. 2.5** Volumetric reconstructions from magnetic resonance imaging showing the inferior or diaphragmatic surfaces of two human hearts. This surface is commonly, and incorrectly, referred to as the posterior surface, based on valentine positioning. The inferior caval vein (IVC) and descending aorta are cut in the short axis; in this region of the thorax, they tend to travel parallel to the long axis of the body. The so-called posterior interventricular sulcus is actually positioned inferiorly and is denoted by a *red star*. A, anterior; L, left; LV, left ventricle; P, posterior; R, right; RV, right ventricle

sulcus (shown with a red star) is more correctly termed “superior.”

## 2.4 Commonly Used Incorrect Terms

This section will specifically describe a few obvious problem areas in which attitudinally incorrect nomenclature is commonly used: the coronary arteries, myocardial segmentation for depiction of infarcts, and cardiac valve nomenclature.

In the normal case, there are two coronary arteries which arise from the aortic root, specifically from two of the three sinuses of Valsalva. These two coronary arteries



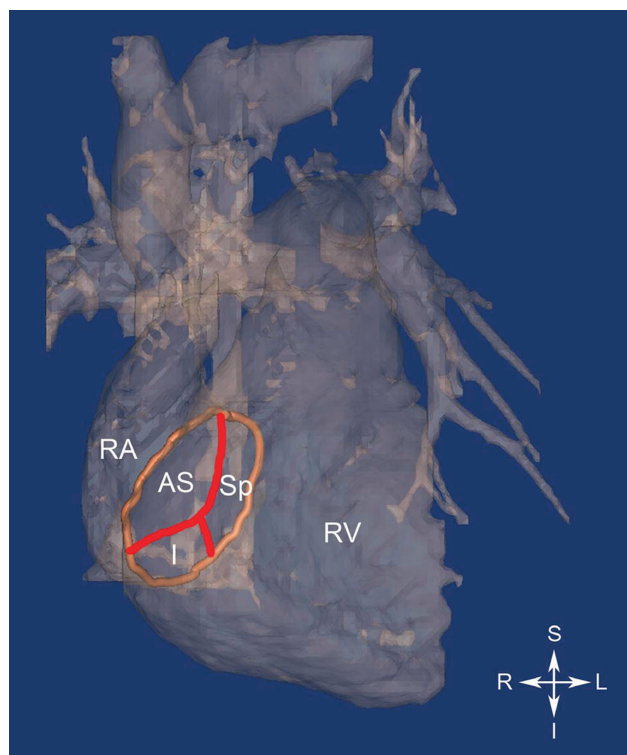
**Fig. 2.6** Volumetric reconstructions from magnetic resonance imaging showing the superior surfaces of two human hearts. In this view the following structures are visible: the superior caval vein (SVC), aortic arch (AoArch) and the major arteries arising from it, the free portion of the right atrial appendage, and the pulmonary trunk (PA) which, after arising from the right ventricle, runs in the transverse plane before bifurcating into the right and left pulmonary arteries. Also, note that the position of the “anterior” interventricular sulcus (shown with a *red star*) is more correctly termed superior. A, anterior; AA, ascending aorta; L, left; LV, left ventricle; P, posterior; R, right; RV, right ventricle

supply the right and left halves of the heart, although there is considerable overlap in supply, especially in the interventricular septum. Nevertheless, the artery which supplies the right side of the heart is aptly termed the “right coronary artery,” and the corresponding artery which supplies the left side of the heart is termed the “left coronary artery.” Therefore, the sinuses in which these arteries arise can be similarly named the right coronary sinus, left coronary sinus, and for the sinus with no coronary artery, the noncoronary sinus; this convention is commonly used. These arteries then branch as they continue their paths along the heart, with the major

arteries commonly following either the atrioventricular or interventricular grooves, with smaller branches extending from them. It is beyond the scope of this chapter to fully engage in a description of the nomenclature for the entire coronary arterial system. However, there are two glaring problems which persist in the nomenclature used to describe the coronary arteries, both of which involve the interventricular grooves. First, shortly after the left coronary artery arises from the left coronary sinus, it bifurcates into the left “anterior descending” and the “left circumflex” arteries. The left “anterior descending” artery follows the so-called “anterior” interventricular groove, which was described previously as being positioned superiorly and to the left and only slightly anteriorly (Fig. 2.3). Second, depending on the individual, either the right coronary artery (80–90%) or the left circumflex supplies the opposite side of the interventricular septum as the left “anterior” descending. Regardless of the parent artery, this artery is commonly called the “posterior” descending artery. However, similar to the so-called “anterior” descending artery, the position of this artery is not posterior but rather inferior (Fig. 2.5).

Now that the courses of the two main coronary arteries are clear, the description of myocardial segmentation needs to be addressed. It is rather interesting that, although clinicians typically call the inferior interventricular artery the posterior descending artery, they often correctly term an infarction caused by blockage in this artery as an inferior infarct. Current techniques used to assess the location and severity of myocardial infarctions include MRI, CT, and 2D, 3D, or 4D cardiac ultrasound. These techniques allow for the clinician to view the heart in any plane or orientation; due to this, a similar confusion in terminology arises. Recently, an American Heart Association working group issued a statement in an attempt to standardize nomenclature for use with these techniques [7]. Upon close examination, this publication correctly terms areas supplied by the inferior interventricular artery as inferior, but incorrectly terms the opposite aspect of the heart as anterior.

Finally, nomenclatures commonly used to describe the leaflets of the atrioventricular valves, the tricuspid, and mitral valves are typically not attitudinally correct. For example, the tricuspid valve is situated between the right atrium and right ventricle, and is so named because, in the majority of cases, there are three major leaflets or cusps. These are currently referred to as the anterior, posterior, and septal leaflets, and were most likely termed in this manner due to examination of the heart in the “valentine” position. Figure 2.7 shows an anterior view of a human heart in an attitudinally correct orientation, with the tricuspid annulus shown in orange. The theorized

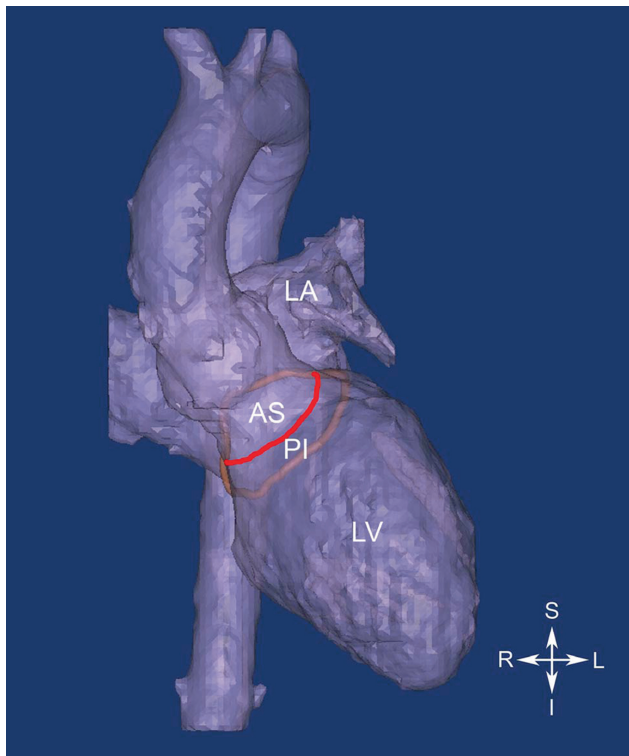


**Fig. 2.7** Volumetric reconstruction from magnetic resonance imaging (MRI) showing the anterior surfaces of the right ventricle and atrium of a human heart. The tricuspid annulus is highlighted in orange, and was traced on the MRI images. The theorized positions of the commissures between the leaflets are drawn in red, and the leaflets are labeled appropriately. AS, anterosuperior; I, inferior; L, left; R, right; RA, right atrium; RV, right ventricle; RV, right ventricle; S, superior; Sp, septal

locations of the commissures between the leaflets are shown in red. In order for the “anterior” leaflet to be truly anterior, the tricuspid annulus would need to be orthogonal to the image. However, the actual location of the annulus is in an oblique plane as shown in the figure, and therefore the leaflets would be more correctly termed anterosuperior, inferior, and septal.

The same is true for the mitral valve, although the terms used to describe it are a bit closer to reality than the tricuspid valve. The mitral valve has two leaflets, commonly referred to as the anterior and posterior. However, Fig. 2.8 shows that the leaflets are not strictly anterior or posterior, or else the plane of the annulus (shown in orange) would be perpendicular to the screen. Therefore, based on attitudinal terms, one would prefer to define these leaflets as anterosuperior and posteroinferior. It should be noted that these leaflets have also been described as aortic and mural, which is less dependent on orientational terms and also technically correct.





**Fig. 2.8** Volumetric reconstruction from magnetic resonance imaging (MRI) showing the anterior surfaces of the left ventricle and atrium of a human heart. The mitral annulus is highlighted in *orange*, and was traced on the MRI images. The theorized positions of the commissures between the leaflets are drawn in *red*, and the leaflets are labeled appropriately. AS, anterosuperior; I, inferior; L, left; LA, left atrium; LV, left ventricle; PI, posteroinferior; R, right; S, superior

## 2.5 Comparative Aspects of Attitudinally Correct Cardiac Anatomy

In addition to the incorrect terminology used to describe the human heart, translation of cardiac anatomy between human and other species is often further complicated due to differences in the orientation of the heart within the thorax. Compared to the human heart, the commonly used large mammalian heart is rotated so that the apex is aligned with the long axis of the body. Furthermore, the apex of the heart is oriented anteriorly, and is commonly attached to the posterior (dorsal) aspect of the sternum. Further confounding the differences is a different nomenclature. The terms inferior and superior are rarely used and are rather replaced by cranial and caudal. Likewise,

the terms anterior and posterior are commonly replaced with ventral and dorsal. Also see Figs. 6.10 and 6.11 for more information on the relative position of a sheep heart compared to a human heart.

## 2.6 Summary

As the field of cardiac anatomy continues to play an important role in the practice of medicine and the development of medical devices, it behooves all involved to adopt commonly used terminologies to describe the heart and its proper location in the body. Furthermore, it may be of great utility to describe the cardiac anatomy of major animal models using the same terminology as that of humans, at least when comparisons are being made between species. Finally, due to advances in 3D and 4-D imaging and their growing use in the cardiac arena, a sound foundation of attitudinally correct terms will benefit everyone involved.

## References

1. Anderson RH, Becker AE, Allwork SP, et al. Cardiac anatomy: An integrated text and colour atlas. London Edinburgh; New York: Gower Medical Pub; Churchill Livingstone, 1980.
2. Anderson RH, Razavi R, Taylor AM. Cardiac anatomy revisited. *J Anat* 2004;205:159–77.
3. Cook AC, Anderson RH. Attitudinally correct nomenclature. *Heart* 2002;87:503–6.
4. Cosio FG, Anderson RH, Kuck KH, et al. Living anatomy of the atrioventricular junctions. A guide to electrophysiologic mapping. A Consensus Statement from the Cardiac Nomenclature Study Group, Working Group of Arrhythmias, European Society of Cardiology, and the Task Force on Cardiac Nomenclature from NASPE. *Circulation* 1999;100:e31–7.
5. McAlpine WA. Heart and coronary arteries: An anatomical atlas for clinical diagnosis, radiological investigation, and surgical treatment. Berlin; New York: Springer-Verlag, 1975.
6. Walmsley R, Watson H. Clinical anatomy of the heart. New York, NY: Edinburgh, Churchill Livingstone (distributed by Longman), 1978.
7. Cerqueira MD, Weissman NJ, Dilsizian V, et al. Standardized myocardial segmentation and nomenclature for tomographic imaging of the heart: A statement for healthcare professionals from the Cardiac Imaging Committee of the Council on Clinical Cardiology of the American Heart Association. *Circulation* 2002;105:539–42.

<http://www.springer.com/978-1-60327-371-8>

Handbook of Cardiac Anatomy, Physiology, and Devices

(Ed.) P.A. Iaizzo

2009, X, 700 p. 414 illus., 214 in color. With CD-ROM.,

Hardcover

ISBN: 978-1-60327-371-8