

Diastolic Heart Failure

MUHAMED SARIC AND ITZHAK KRONZON

● PRACTICAL POINTS

- Diastole starts with the closure of the aortic valve and ends with the closure of the mitral valve.
- It consists of four phases: isovolumic relaxation time (IVRT), early or rapid ventricular filling, diastasis, and late filling or atrial contraction phase
- During IVRT, there is no blood flow or filling from the atria to the ventricles; it represents the time period between the aortic valve closure and the mitral valve opening.
- Diastolic dysfunction is characterized by abnormal active and passive relaxation properties of the left ventricle (LV), a rise in the LV diastolic pressures, and a rise in the left atrial (LA) pressures aimed at maintaining an LA to LV pressure gradient that is necessary for LV filling.
- Pseudonormal and restrictive patterns arise because the elevation in the LA to LV pressure gradient leads to an increase in the mitral E wave peak velocity, an increase in the mitral E/A ratio, and a shortening of both IVRT and DT.
- An abnormal relaxation pattern (Grade I or mild LV diastolic dysfunction) is characterized by IVRT prolongation, a mitral A wave taller than the E wave ($E < A$), a prolonged deceleration time (DT) of the mitral E wave, and a taller S wave than D wave on pulmonary venous flow velocity.
- A pseudonormal relaxation pattern (Grade II or moderate LV diastolic dysfunction) is characterized by an E/A ratio between 1 and 2.
- A restrictive filling pattern (Grade III or severe LV diastolic dysfunction) occurs when the E/A becomes >2 and the DT of the mitral E wave shortens to below 150 msec.
- True diastolic heart failure is a result of an upward and leftward shift in the EDPVR curve as a result of the combined effects of impaired LV relaxation and increased LV stiffness, which leads to LV end-diastolic pressure elevation even at normal or low LV filling volumes.
- About 50% of patients presenting with signs and symptoms of heart failure have a normal or near-normal ejection fraction (HFNEF) without another explanation; risk factors for HFNEF include age, female gender, systemic hypertension, LV hypertrophy, and diabetes mellitus.

INTRODUCTION

AQ1 Ventricular diastole (from the Greek $\alpha\lambda\lambda\alpha\sigma\tau\omicron\lambda\epsilon$: diastolê—“dilation”) is the filling portion of the cardiac cycle, which has traditionally been defined by events heard during cardiac auscultation. It starts with the closure of the aortic valve and ends with the closure of the mitral valve. Electrocardiographically, mechanical diastole lasts from the peak of the T wave to the peak of the R wave.

NORMAL AND ABNORMAL LV VENTRICULAR DIASTOLIC FUNCTION

The diastolic period during sinus rhythm is divided into four phases: (1) isovolumic relaxation time (IVRT) between the aortic valve closure and the mitral valve opening devoid of blood flow from the atria into the ventricles; (2) early or rapid ventricular filling (RVF); (3) diastasis, an intermezzo period with usually little or no appreciable ventricular filling;

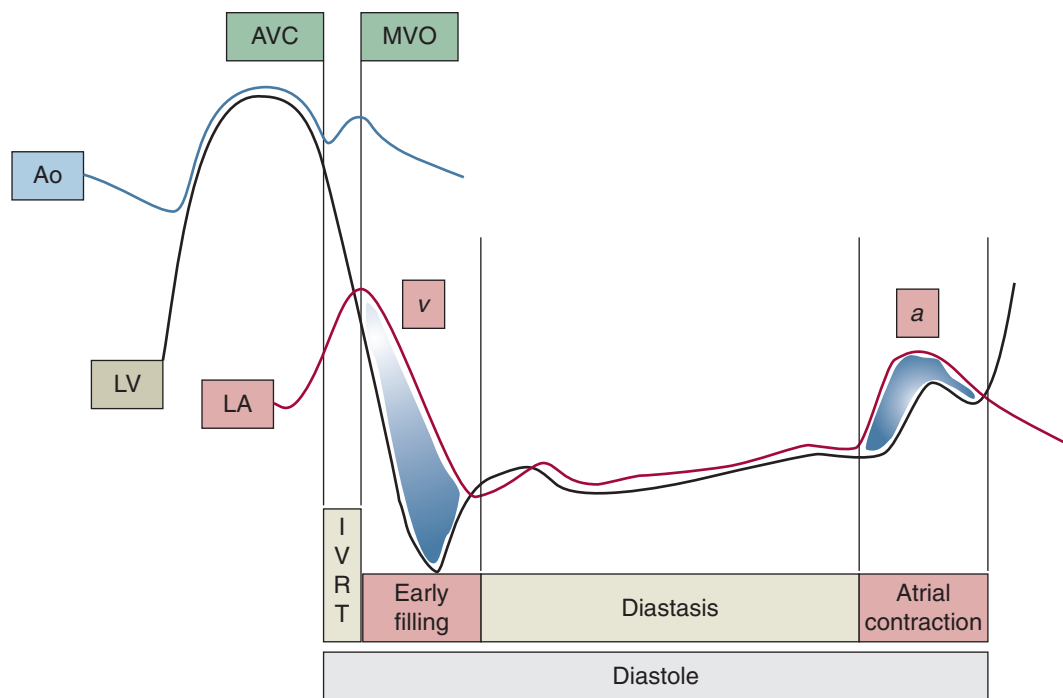


FIGURE 58-1. Phases of diastole Phases of diastole based on the intracardiac pressure measurement of the left atrium (LA), left ventricle (LV), and the aorta (Ao): [1] IVRT, isovolumic relaxation time; [2] E, early or passive filling phase; [3] diastasis; [4] A, atrial kick. AVC, aortic valve closure. MVO, mitral valve opening. *v*, ventricular wave; *a*, atrial wave of LA pressure curve.

and (4) late filling or atrial contraction phase (**Figure 58-1**). The atrial contraction phase is either abolished or becomes asynchronous with other ventricular events during atrial arrhythmias and atrioventricular block.

These four phases occur simultaneously in the right and left ventricles. In this chapter, we will concentrate on the events in the left ventricle.

Echocardiographic Correlates of Diastolic Phases

After placing a pulsed spectral Doppler sample volume at the mitral leaflet tips, one obtains a flow velocity recording (depicted in **Figure 58-2**), a horizontal axis representing time, and a vertical axis representing blood velocity.

During each of the two filling phases, a distinct antegrade (above the baseline) wave is inscribed: E wave during rapid ventricular filling, and A wave during atrial contraction. As seen in **Figure 58-1**, the flow of blood from the left atrium into the left ventricle is the result of the left atrial pressure exceeding the left ventricular pressure in those two phases of diastole.

The time interval between the peak of the E wave and the end of the E wave is referred to as deceleration time (DT)

and is inversely related to the rate of left ventricular relaxation and the magnitude of the pressure gradient between the left atrium and the left ventricle.

Because no ventricular filling occurs during IVRT, a flat line is inscribed on the echocardiographic flow velocity tracings. The length of this line segment represents the duration of IVRT. Like DT, IVRT is inversely related to the rate of left ventricular relaxation and the magnitude of the pressure gradient between the left atrium and the left ventricle. Normal E, A, DT, and IVRT values are given in **Table 58-1**.

Because no appreciable filling occurs during diastasis in normal individuals, a flat line is usually inscribed between the E and A waves. The length of this line segment is inversely related to heart rate. Given the absence of significant flow during diastasis, tachycardia (unless extreme) is not detrimental to left ventricle filling in a normal individual.

When left ventricular relaxation is delayed, early left ventricular filling may continue past the E wave into the diastasis. The presence of an antegrade wave (sometimes referred to as L wave) in diastasis with a peak velocity >20 cm/sec is indicative of left ventricular diastolic dysfunction (**Figure 58-3**).

AQ2

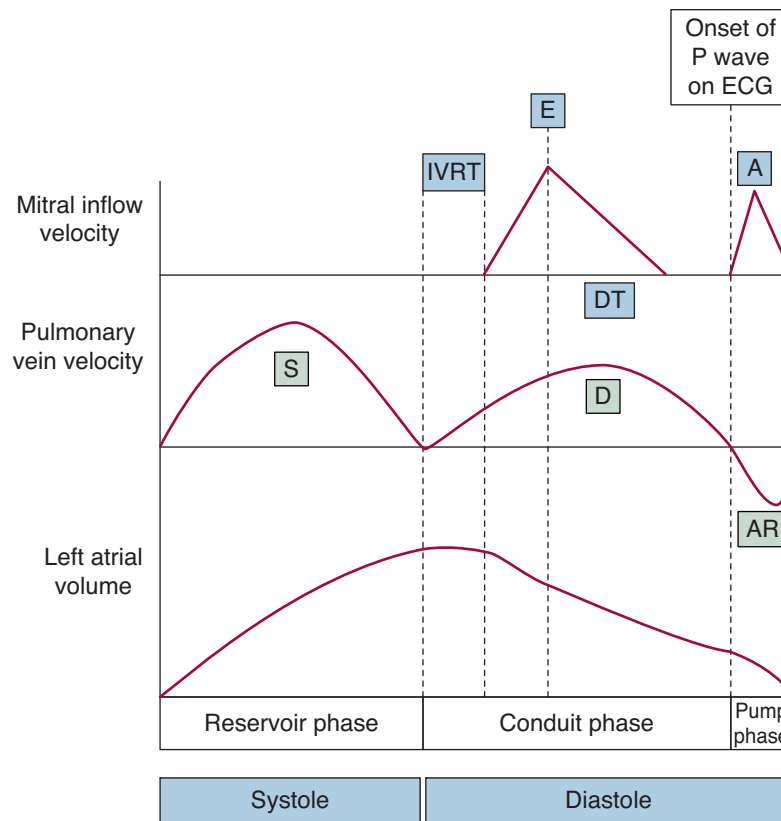


FIGURE 58-2. Schematic representation of mitral and pulmonary venous flow velocity patterns, and left atrial volume. Mitral inflow: IVRT, isovolumic relaxation time; E, early filling; DT, deceleration time; A, atrial contraction. Pulmonary vein: S, systolic; D, diastolic wave; AR, atrial reversal wave.

Filling in Early Versus Late Diastole in a Normal Ventricle

Ventricular filling is driven primarily by a pressure gradient between the left atrium and the left ventricle. However, the pressure difference during rapid ventricular filling arises from a fundamentally different reason compared to the atrial contraction phase.

TABLE 58-1 • Normal Values of Mitral Inflow Parameters

Mitral Value Parameter	AGE (years)		Change with Age
	<50	>50	
IVRT (msec)	65–89	73–107	↑
E_{max} (cm/s)	58–86	48–76	↓
DT (msec)	159–199	174–246	↑
A_{max} (cm/s)	30–50	45–73	↑
E_{max}/A_{max}	1.3–2.5	0.8–1.4	↓

IVRT, isovolumic relaxation time; DT, deceleration time; E, early or passive filling phase; A, atrial kick.

During rapid ventricular filling in a normal individual, the left ventricular pressure falls below the left atrial pressure through active and passive relaxation of the left ventricle. In contrast, during the atrial contraction phase, the left ventricular filling occurs because the left atrial pressure rises above the left ventricular pressure. In other words, the rapid ventricular filling phase is primarily driven by active relaxation of the left ventricle, whereas the atrial contraction phase is driven by the systolic properties of the left atrium. In a normal individual, the rapid filling phase flow accounts for about three quarters of the total diastolic flow volume, and the atrial contraction phase for the remaining one quarter of the total.

Mechanical Performance of Left Ventricle During Diastole

Left ventricular dilation during diastole involves both active and passive forces.

Active Relaxation

Left ventricular relaxation in early diastole is a load-dependent and energy consuming process. The energy in the form of adenosine triphosphate (ATP) is used

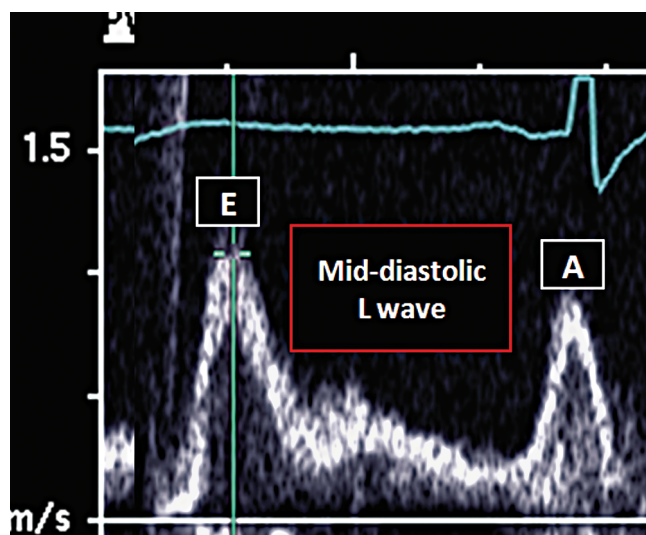


FIGURE 58-3. Mid-diastolic wave. Spectral Doppler recordings of the mitral blood inflow reveal abnormal mid-diastolic L wave of an A peak velocity >20 cm/sec, indicative of left ventricular myocardial dysfunction.

to uncouple actin-myosin bridges and to remove cytosolic calcium ions into the sarcoplasmic reticulum via SERCA (sarco/endoplasmic reticulum Ca^{2+} ATP-ase).

At the end of the preceding ventricular systole, the left ventricle completes its torsional deformation and assumes a shape similar to that of a wrung towel. The untwisting of the left ventricular apex in the counterclockwise direction and the ventricular base in the clockwise fashion is the first mechanical event of diastole. As a result, the left ventricle undergoes lengthening in its long and short axes (longitudinal and circumferential strains become positive), and its wall decreases in thickness (radial strain becomes negative).

These mechanical events of active myocardial relaxation of the ventricle start with the onset of IVRT and are essentially completed by the end of the rapid filling phase but occasionally may extend into diastasis. The gold standard for the assessment of active myocardial relaxation is the time constant τ (tau), calculated from the left ventricular pressure curve obtained invasively by high-fidelity pressure transducers during cardiac catheterization. The value of τ represents the time constant of the exponential decay of the left ventricular pressure during IVRT. A τ value that is longer than 48 milliseconds indicates abnormal LV relaxation.

Echocardiographically, active relaxation properties are assessed either indirectly from the mitral blood flow velocity tracings or directly by tissue Doppler recordings from the mitral annulus.

Abnormal left ventricular relaxation (unless masked by concomitant left atrial pressure elevation) is characterized

by prolongation of both IVRT and DT; these two parameters shorten with the rise of left atrial pressure (see below).

AQ3

By combining the color Doppler and M mode imaging over the left ventricle during diastole, one can determine the rate at which the E wave propagates from the mitral leaflet tips to the left ventricular apex; this rate is referred to as flow propagation velocity or V_p . The more impaired the left ventricular relaxations are, the lower the value of V_p (Figure 58-4).

Using the tissue Doppler technique after placing the sample volume at the level of either medial or lateral mitral annulus, one can record the velocities of left ventricular lengthening in the longitudinal direction during diastole (as well as shortening during ventricular systole). During diastole, tissue Doppler recordings reveal two negative (below the baseline) waves that are simultaneous with the blood velocity E and A waves; they are referred to as E and A waves. The more impaired the left ventricular relaxations are, the lower the peak E velocity (Figure 58-4). The amplitude of the E wave continues to decline with the worsening of left ventricular diastolic dysfunction and, in principle, is not affected by left atrial pressure (preload). In other words, E may be considered as a surrogate of tau.

Passive Recoil

Active ventricular relaxation is augmented by the passive recoil of the ventricular myocardium, pericardium, and the surrounding thoracic tissue. The passive diastolic property of the ventricle is expressed as either the ventricular stiffness (dP/dV) or its inverse, the LV compliance (dV/dP), where P is the LV pressure and V is the LV volume.

This relationship between LV volume and pressure has traditionally been studied at end-diastole using the end-diastolic volume-pressure relationship (EDVPR) curve. This curve represents the lower boundary of a series of LV volume-pressure curves obtained at various preloads (see chapter on cardiac catheterization).

Because EDPRV is not linear, the stiffness varies along the EDVPR curve; the LV becomes stiffer as the end-diastolic volume increases. In addition, when the LV myocardium hypertrophies (as in hypertrophic cardiomyopathy) or accumulates inelastic extracellular matrix substances (as in myocardial fibrosis or amyloidosis), the EDVPR curve shifts upward and leftward. This shift indicates that LV end-diastolic pressure has risen above normal levels, even at normal LV filling volumes. Conversely, when the LV remodeling leads to an increase in end-diastolic volume (as in systolic LV dysfunction), the EDVPR curve shifts downward and rightward (Figure 58-5).

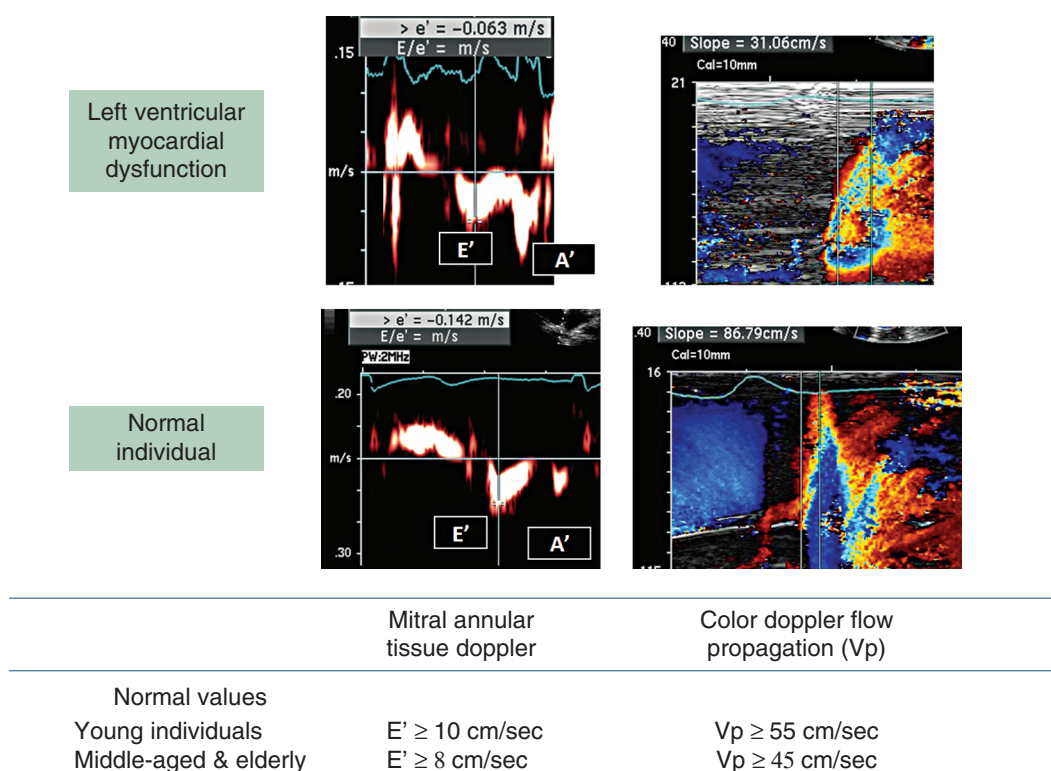


FIGURE 58-4. Mitral annular tissue Doppler and flow propagation velocity. Mitral annular tissue Doppler velocities reveal E and A waves. Flow propagation velocity on above color Doppler recordings is referred to as “slope.”

The value of LV stiffness modulus, a measure of dP/dV , can be derived from pressure-volume tracings obtained invasively by high-fidelity pressure transducers during cardiac catheterization. LV stiffness modulus is the chamber stiffness constant (b) of an exponential curve fit to the diastolic LV pressure and volume points:

$$P = a \times e^{V \times b} + c$$

where P = LV pressure, V = LV volume, b = chamber stiffness constant, and a ; c = asymptote and intercept of the relation.

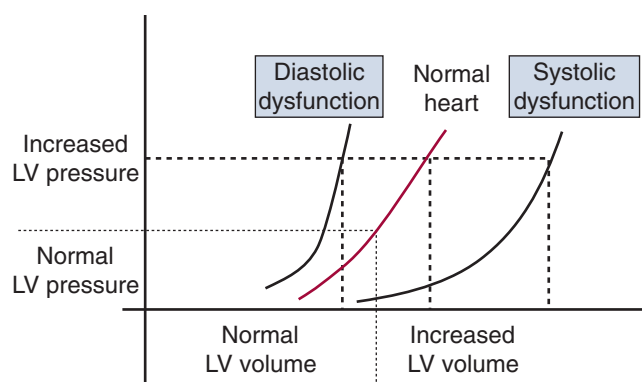


FIGURE 58-5. End-diastolic pressure-volume relationship.

An LV stiffness constant (b) value that is greater than 0.27 is indicative of an abnormally stiff LV.

Although conceptually very useful, ventricular stiffness and compliance are not used in routine clinical practice because of the complexity involved in their determination.

In this chapter, the discussion will be restricted to the myocardial aspect of the left ventricular diastolic function; the effect of the pericardial sac distensibility and the function of the surrounding thoracic tissue are discussed elsewhere.

Left Atrial Performance

During different parts of the cardiac cycle, the left atrium serves as a reservoir, a conduit, and a pump. During ventricular systole, the mitral valve is closed and the left atrium serves as a reservoir. The filling of the left atrium is enhanced by the descent of the mitral annulus toward the left ventricular apex. This leads to an increase in atrial volume, which reaches its maximum at the end of ventricular systole. It is this maximum volume at the end of the reservoir phase that is reported as the “left atrial volume” when assessing the left ventricular diastolic function. Indexed for body surface area, normal left atrial volume is <28 mL/m². With chronic elevation of LA pressures (whether due to LV systolic or diastolic heart failure), the LA volume index

progressively increases (Table 58-2) and with it a risk of the development of atrial fibrillation.

The left atrial reservoir, conduit, and pump phases can be studied echocardiographically by pulmonary venous flow velocity tracings obtained after placing a spectral pulsed Doppler sample volume inside a pulmonary vein, some 1 to 2 cm from the pulmonary vein-left atrial junction (Figure 58-6 and Figure 58-7). On transthoracic echocardiography, the recordings are usually made from the right upper pulmonary vein in the apical four-chamber view,

Table 58-2 • Left Atrial (LA) Volume Indexed for Body Surface Area	
	LA Volume Index (mL/m ²)
Normal	<28
Mild Dilation	29–33
Moderate Dilation	34–39
Severe Dilation	>40

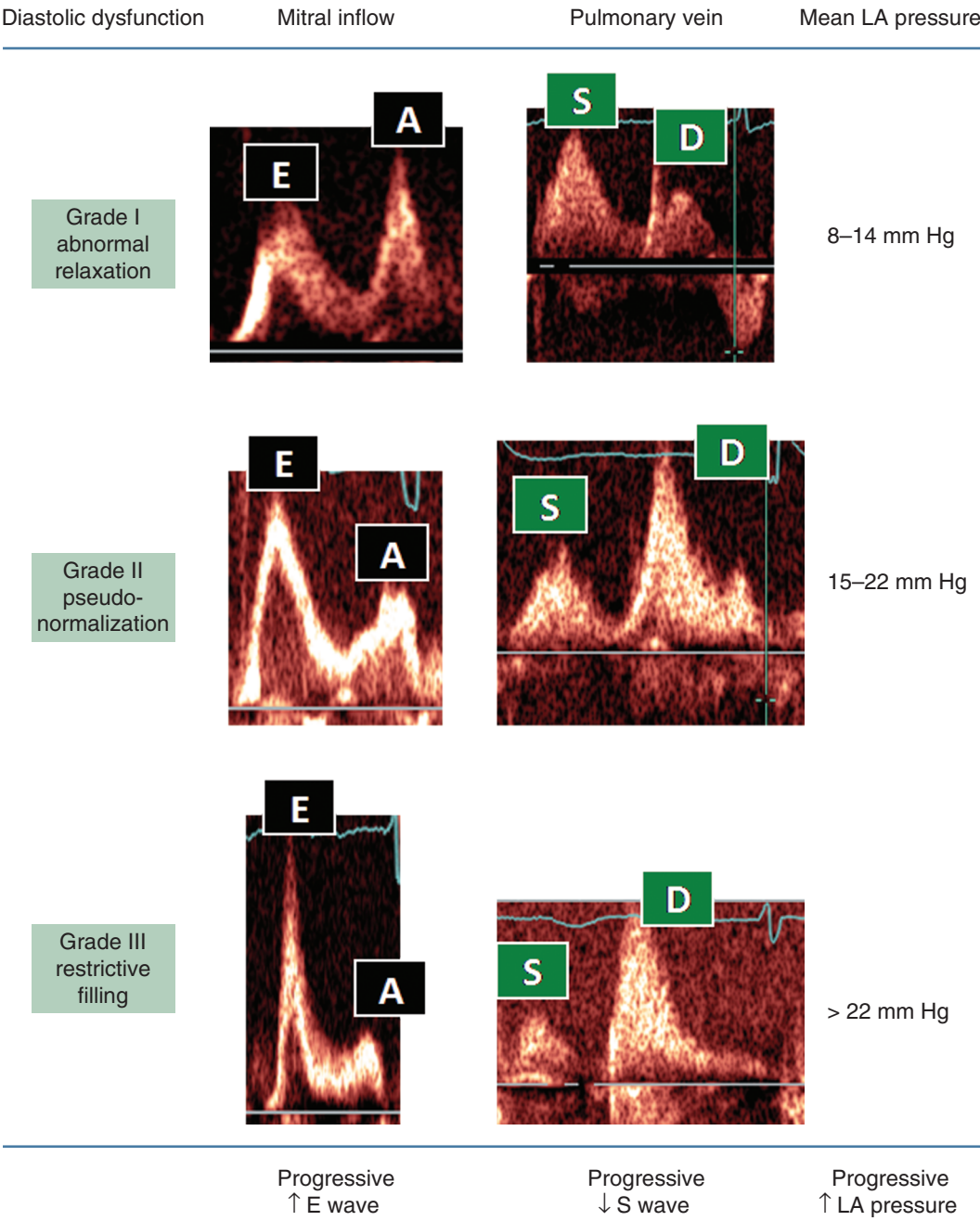


FIGURE 58-6. Grades of diastolic dysfunction. Mitral inflow: E, early filling; A, atrial kick. Pulmonary vein: S, systolic; D, diastolic wave.

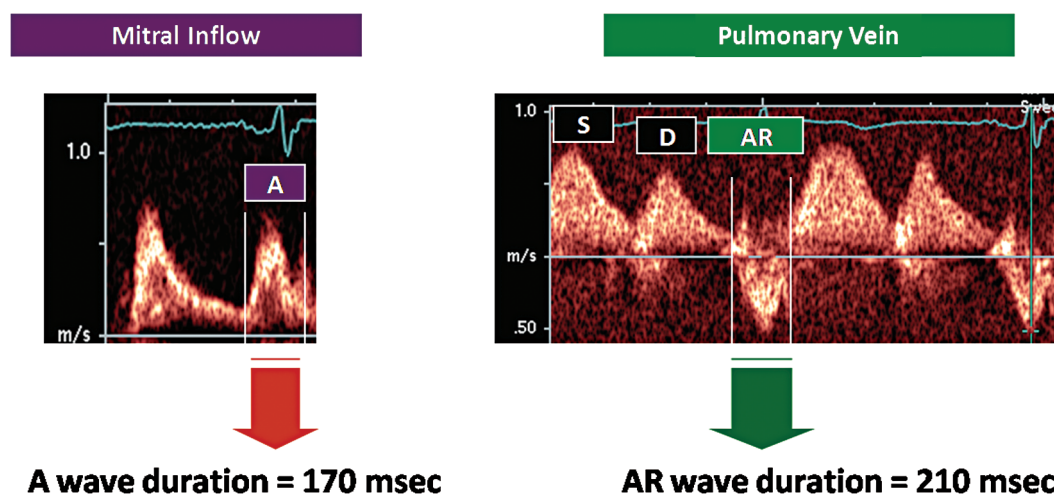


FIGURE 58-7. Mitral a wave vs. pulmonary venous reversal wave duration. When the duration of the pulmonary venous reversal wave (AR) lasts more than 30 milliseconds greater than that of the mitral A wave, left ventricular end-diastolic pressure is elevated (>15 mm Hg), as in the above example.

and from the left upper pulmonary vein on transesophageal echocardiography.

The reservoir phase, which finishes at the end of IVRT, is represented by the S (systolic) wave on pulmonary venous flow velocity spectral Doppler tracings.

The conduit phase encompasses the mitral E wave and the diastasis and is characterized by the D (diastolic) wave in the pulmonary venous flow velocity tracings. The flow of blood from the left atrium to the left ventricle is governed by the pressure gradient between the left atrium and the left ventricle. The higher the pressure gradient, the taller the D wave is.

In individuals who are in sinus rhythm, the atrial contraction is the final phase of the ventricular filling. Following the P wave on the electrocardiogram, atrial contraction propels the blood in two opposite directions: (1) forward across the mitral valve into the left ventricle, and (2) retrograde into the valveless pulmonary veins. During this phase, an atrial reversal (AR) wave is inscribed in the pulmonary venous spectral Doppler tracings; its timing partly overlaps with the mitral A wave.

When the left ventricular pressure is elevated, the peak velocity of the AR wave is greater than 35 cm/sec (assuming a sinus rhythm and preserved left atrial systolic function), and it outlasts the left ventricular A wave by 30 milliseconds or more (Figure 58-7).

Normal Versus Abnormal Filling Patterns

In normal young individuals, the mitral blood velocity inflow is characterized by a short IVRT, an E wave higher than the A wave ($E > A$), and the short deceleration time of the E wave. The pulmonary venous flow pattern is usually

characterized by an S wave smaller than the D wave ($S < D$), and the AR wave is short and has a peak velocity less than 35 cm/sec. The peak velocity of the mitral annular tissue E wave is greater than 12 cm/sec, and the flow propagation velocity (V_p) of the E wave on color M mode is greater than 55 cm/sec. Because the sucking effect of the rapidly relaxing left ventricle during early diastole is the predominant force driving LV filling, the hearts of young and middle-age individuals are said to be “suckers.”

Diastolic dysfunction is characterized by three overlapping processes: (1) myocardial dysfunction of the left ventricle due to abnormal active and passive properties of the left ventricle; (2) a rise in the left ventricular diastolic pressure; and (3) a rise in the left atrial pressure aimed at maintaining LA to LV pressure gradient that is necessary for left ventricular filling.

Early in the progression of left ventricular dysfunction, the loss of active relaxation predominates; this phase is referred to as abnormal relaxation. In later stages, abnormal relaxation still exists; but on mitral and pulmonary venous flow velocity tracings, its presence is masked by the effects of ever rising filling pressures. As the LV diastolic dysfunction progresses, the filling patterns first become pseudonormal and then restrictive.

Pseudonormal and restrictive patterns arise because elevation in the LA to LV pressure gradient leads to an increase in the mitral E wave peak velocity, an increase in the mitral E/A ratio, and shortening of both IVRT and DT. If one plots the mitral blood flow E/A ratio against the left atrial pressure, a U-shaped curve is obtained (Figure 58-8).

In pulmonary venous tracings, the peak S wave velocity progressively diminishes and becomes lower than that of the D wave. In addition, the peak velocity of the AR wave rises above 35 cm/sec (assuming sinus rhythm and preserved left

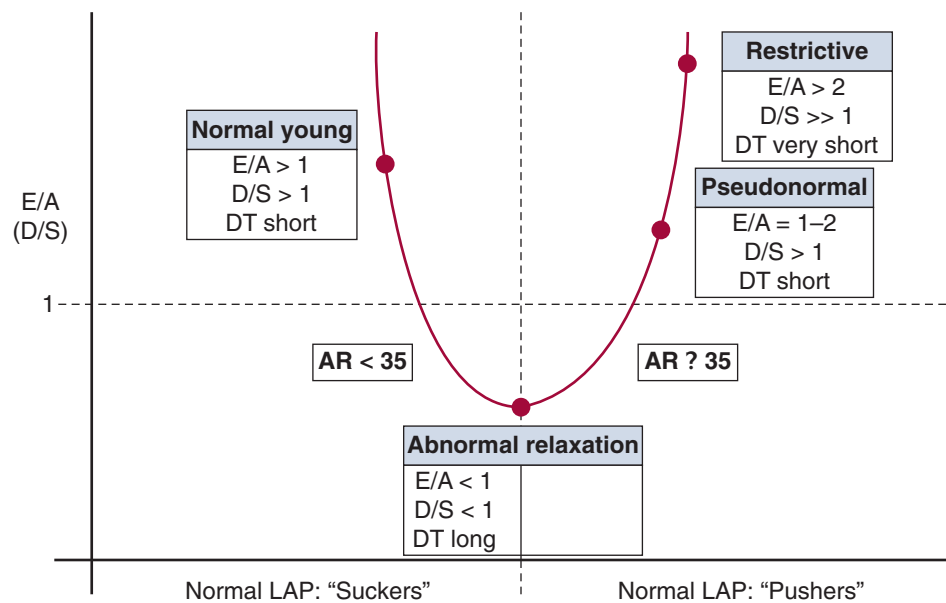


FIGURE 58-8. The U-shaped curve of left ventricular diastolic dysfunction. For left ventricular filling, normal individuals primarily rely on rapid left ventricular (LV) relaxation (sucking) during the E phase. With mild LV diastolic dysfunction (abnormal relaxation), the E phase filling is accomplished by prolongation of the E wave deceleration time (DT) and the shifting of the filling to the A phase. When that adaptation is not sufficient to fill the LV properly, the left atrial pressure rises to push the blood into the LV (pseudonormal and restrictive grades). Mitral inflow: E, early wave; A, atrial kick. Pulmonary venous flow: S, systolic; D, diastolic; AR, atrial reversal wave.

atrial systolic function), and its duration exceeds that of the mitral A wave by greater than or equal to 30 msec.

Although the increase in the LA to LV pressure gradient in individuals with advanced diastolic dysfunction alters the mitral and pulmonary venous filling patterns to mask the presence of abnormal LV relaxation, such masking is not observed in mitral tissue Doppler and Vp tracings. The mitral annular tissue Doppler peak E velocity and the Vp progressively diminish as the LV dysfunction advances, which confirms the continued presence of abnormal LV relaxation in advanced LV diastolic dysfunction.

In summary, most individuals with diastolic dysfunction have a LV filling pattern driven by a high LA to LV pressure gradient in the presence of abnormal left ventricle relaxation during early diastole. Descriptively, such individuals are referred to as “pushers.”

Numeric values for various diastolic patterns are summarized in Table 58-3.

DIASTOLIC DYSFUNCTION FILLING PATTERNS

(1) **ABNORMAL RELAXATION PATTERN** (also referred to as Grade I or mild LV diastolic dysfunction) is characterized by IVRT prolongation, a mitral A wave taller than

the E wave ($E < A$), and prolonged DT. The pulmonary venous flow velocity pattern is characterized by an S wave that is taller than the D wave ($S > D$); the AR wave increases in peak velocity and duration. The mitral annular tissue Doppler tracings reveal a diminished peak E velocity (<8 cm/sec). The flow propagation velocity (Vp) slows to below 45 cm/sec.

An abnormal relaxation pattern is frequently observed in elderly individuals. Some researchers view this as a benign sign of aging (akin to gray hair), whereas others consider it a truly pathologic process (akin to osteoporosis).

A worsening of the LV diastolic function occurs as a continuum from abnormal relaxation through pseudonormalization to restrictive filling.

TABLE 58-3 • Diastolic Filling Patterns

Parameter	IVRT (msec)	DT (msec)	E/A (cm/sec)
Normal Adult	<100	<220	>1
Grade I: Delayed Relaxation	>100	>220	<1
Grade II: Pseudonormalization	60–100	150–200	1–2
Grade III: Restriction	<60	<150	>2

IVRT, isovolumic relaxation time; DT, deceleration time; E, early or passive filling phase; A, atrial kick.

(2) **PSEUDONORMAL FILLING PATTERN** (Grade II or moderate LV diastolic dysfunction) is characterized by an E/A ratio between 1 and 2.

(3) **RESTRICTIVE FILLING** (Grade III or severe LV diastolic dysfunction) occurs when the E/A becomes greater than 2 and the deceleration time of the mitral E wave shortens to below 150 msec.

It is important to emphasize that E/A and D/S ratios reflect, primarily, the magnitude of the pressure gradients between respective cardiac chambers (LA to LV pressure gradient in the case of E/A ratio, and pulmonary vein to LA pressure gradient in the case of D/S ratio). Thus, these ratios by themselves cannot tell us whether the left ventricular diastolic function is normal or abnormal.

For instance, the same 3-mm Hg pressure gradient between the left atrium and the left ventricle (and thus the same E/A and D/S ratios) may occur with normal filling pressures (as in a young individual whose mean LA may be 5 and the LV pressures may be 2 mm Hg during the rapid filling phase), as well as in someone with left ventricular dysfunction whose mean LA and LV pressures are 17 and 14 mm Hg, respectively.

Because pseudonormal and restrictive patterns reflect both abnormal LV relaxing properties and elevated filling pressures, maneuvers that diminish LA pressure (such as Valsalva maneuver or diuresis) will lead to a decrease in the E/A and D/S ratios. Thus, a restrictive pattern may turn into a pseudonormal pattern, and the pseudonormal pattern may revert to an abnormal relaxation pattern after such maneuvers. A decrease in the E/A ratio by more than 0.5 units (e.g. E/A ratio change from 1.4 to less than 0.9) is considered diagnostic and is an important discriminator between normal and pseudonormal filling patterns. (In addition, a pseudonormal pattern is characterized by elevated filling pressures and an increase in LA volume, neither of which are present in hearts with a normal filling pattern; see below.)

AQ4

(4) **IRREVERSIBLE RESTRICTIVE PATTERN** (Grade IV diastolic dysfunction). Individuals with a restrictive filling pattern, in whom the E/A ratio does not change significantly after preload-lowering maneuvers, have an extremely severe form of diastolic dysfunction (Grade IV). They have an extremely poor prognosis with a survival rate of less than 50% at 2 years.

Echocardiographic Estimation of LV Filling Pressures

In general, estimation of instantaneous filling pressures by echocardiography is based on a ratio of a peak blood velocity during rapid ventricular filling (the height of the mitral E wave is directly proportional to the LA to LV pressure

gradient) and the corresponding marker of LV relaxation (either the E velocity of the mitral annular tissue Doppler, or the V_p). Left atrial pressure estimation by E/E' ratio is given in **Table 58-3**.

Mean pulmonary artery wedge pressure (PAWP) can be estimated from the following two equations:

$$\text{[Equation 1]} \quad \text{PAWP} = 1.9 + 1.24 \times \text{E/E}'$$

$$\text{[Equation 2]} \quad \text{PAWP} = 4.6 + 5.27 \times \frac{E}{V_p}$$

Elevation of LV filling pressures occurs in symptomatic heart failure and the degree of pressure elevation correlates well with the magnitude of the patient's symptoms. It is important to emphasize that the filling pressure elevation in systolic heart failure occurs with increased LV volumes (a rightward and downward shift in the diastolic pressure-volume relationship compared to normal), whereas the pressure elevation in diastolic heart failure occurs at normal or small LV volumes (a leftward and upward shift in the diastolic pressure-volume relationship compared to normal). These changes are depicted in **Figure 58-5**. Normal LV end-diastolic volume is less than 97 mL/m², whereas the normal end-systolic volume is less than 49 mL/m².

Left Atrial Volume as an Indicator of LV Diastolic Dysfunction

The E/E' and E/V_p ratios mentioned above give only a point estimate of the filling pressures at a particular moment in time. Left ventricular dysfunction is characterized by chronically elevated LA pressures resulting in left atrial enlargement. Thus, an increase in LA size is an indicator of chronically elevated filling pressures. The higher the grade of LV diastolic dysfunction, the larger the LA size is. The LA size should be expressed as LA volume indexed for body surface area; LA anteroposterior diameter should not be used for such a purpose, as it poorly correlates with the actual LA volume.

Although chronic LV diastolic dysfunction invariably leads to LA enlargement, not all LA enlargements are due to LV diastolic dysfunction. LA enlargement due to chronic volume overload (such as with mitral regurgitation or in marathon runners) or pressure overload due to valvular disease (such as mitral stenosis) should be excluded before attributing LA enlargement to LV diastolic dysfunction.

DIASTOLIC HEART FAILURE

Heart failure, whether systolic or diastolic, has classically been recognized as a clinical triad of breathlessness, fatigue, and fluid overload. Breathlessness is caused by elevated left atrial pressure, which leads to alteration of diastolic filling

patterns as visualized echocardiographically by mitral and pulmonary venous Doppler flow velocity indices. The LA pressure is either normal or mildly elevated in individuals with the abnormal relaxation pattern. It is moderately elevated in individuals with the pseudonormal pattern and severely elevated in those with the restrictive pattern. In other words, mitral and pulmonary venous Doppler flow indications are well correlated with the severity of the patient's heart failure symptoms. However, it is important to emphasize that the mitral and pulmonary venous Doppler flow indices alone cannot differentiate between diastolic and systolic heart failure. By observing Doppler filling indices, one can conclude whether the LA pressure during diastole is normal or abnormal but not infer whether the LV diastolic function is normal or abnormal.

True diastolic heart failure is a result of an upward and leftward shift in the EDPVR curve as a result of the combined effects of impaired LV relaxation and increased LV stiffness, which leads to LV end-diastolic pressure elevation even at normal or low LV filling volumes. In contrast, systolic heart failure is characterized by LA pressure elevation only at high filling volumes due to a rightward and downward shift in the EDRPV curve. As seen in **Figure 58-5**, the same LA pressure elevation (and consequently the same LV Doppler filling indices) can be observed in patients with either diastolic or systolic heart failure.

It is now recognized that this symptomatic phase (ACC/AHA Stages C and D; **Figure 58-9**) is a late manifestation of a disease process that might have started years or even decades earlier. In AHA/ACC Stage A, diastolic heart failure is initiated by disease-specific risk factors (such as age and hypertension in so-called normal LVEF heart failure syndrome). In Stage B, LV remodeling occurs, characterized by an increase in left ventricular wall thickness (concentric LV hypertrophy) and progressive left atrial enlargement.

Once patients reach Stages C and D, they can be in any of the four New York Heart Association symptom classes (Class I: symptoms only at levels of exertion that would limit normal individuals; Class II: symptoms on ordinary exertion; Class III: symptoms at less-than-ordinary exertion; or Class IV: symptoms at rest).

TYPES OF DIASTOLIC HEART FAILURE

There is no universally agreed upon definition of diastolic heart failure (DHF). It may occur in conjunction with either normal or abnormal LV systolic function.

Conceptually, isolated DHF could be defined as a combination of signs and symptoms of heart failure and LV diastolic dysfunction. The clinical impression of heart failure can be corroborated by objective signs of pulmonary vascular congestion on a chest radiograph, increased brain natriuretic peptide (BNP) serum levels, and the demonstration of elevated left atrial pressures either invasively or echocardiographically.

A direct demonstration of LV diastolic dysfunction would require a determination of abnormal values of tau and LV stiffness modulus, as well as the demonstration of a pathologic substrate through an endomyocardial biopsy. However, such measurements are complex and, as pointed earlier, not routinely used in clinical practice. As a consequence, there are only very few conditions with well-characterized LV diastolic dysfunctions that lead to DHF. These include hypertrophic cardiomyopathy (discussed elsewhere) and infiltrative cardiomyopathies, which are discussed below.

Instead, the presence of LV diastolic dysfunction in most patients with presumed DHF is inferred. In such individuals, LV diastolic dysfunction is suspected because they present with heart failure in the setting of normal or near-normal

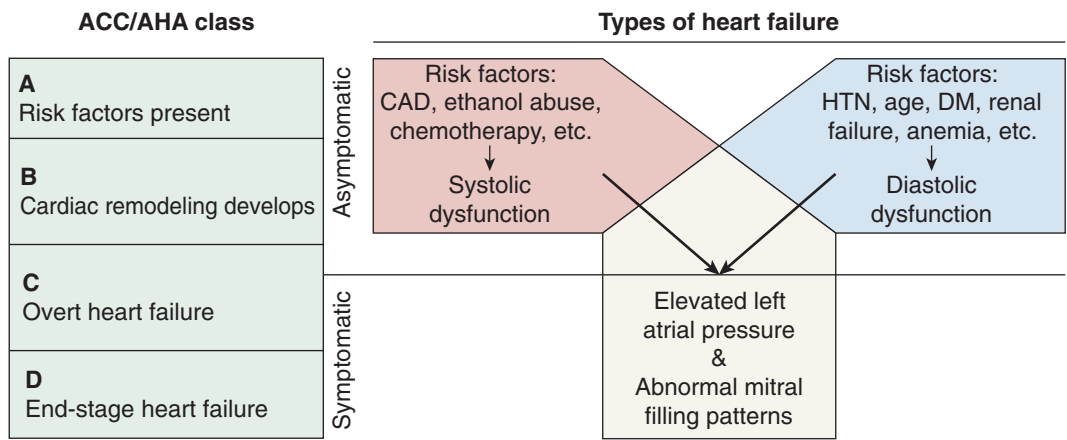


FIGURE 58-9. Types and stages of heart failure. Stages A, B, C, & D refer to the American College of Cardiology (ACC) and American Heart Association classification of heart failure. CAD, coronary artery disease; HTN, systemic hypertension; DM, diabetes mellitus.

LV systolic function (LV ejection fraction $\geq 50\%$), normal or small LV diastolic volumes, and no significant valvular heart disease. Because the stiffness is defined as dp/dv , the presence of elevated filling pressures in the setting of normal LV volume is indicative of increased LV stiffness and, by extension, true LV diastolic dysfunction.

According to an American Heart Association position paper from 2000, DHF can be defined as either probable or definitive. *Probable* DHF is simply defined as the presence of clinical signs and symptoms of heart failure within 72 hours of detecting normal or near-normal LV systolic function and no significant valvular disease. The diagnosis of *definitive* DHF also requires detection of abnormal LV diastolic function by Doppler echocardiography.

Because a definitive diagnosis of DHF requires extensive expertise in echocardiographic assessment of LV diastolic function, epidemiologic studies routinely define DHF along the probable DHF criteria. Because LV diastolic dysfunction is infrequently measured directly in such studies, some prefer the term *heart failure with normal LV ejection fraction* to that of DHF, when applied to patients in these studies.

In 2007, the European Society of Cardiology made the DHF diagnostic criteria even more stringent; it defined isolated DHF as a condition with clinical signs and symptoms of heart failure, normal LV systolic function, abnormal Doppler filling patterns, and the presence of elevated LV filling pressures (defined as one or more of the following: LV end-diastolic pressure >16 mm Hg; mean pulmonary artery wedge pressure >12 mm Hg; and an $E/E' >15$) in the setting of normal LV end-diastolic volume (97 mL/m^2).

DIASTOLIC HEART FAILURE DUE TO INFILTRATIVE DISORDERS

Infiltrative myocardial disorders (restrictive cardiomyopathies) are rare causes of DHF. Although such cardiomyopathies are infrequent, the presence of DHF in affected individuals is the norm. LV distensibility in these patients decreases due to deposition of various substances either in the extracellular matrix of the heart muscle (such as proteins in amyloidosis and myocardial fibrosis; and small molecules in hyperoxaluria) or in the cardiac lysosomes.

AMYLOIDOSIS is a systemic multiorgan disorder caused by extracellular deposition of normally soluble amyloidogenic proteins in various organs including the heart. Amyloid fibrils are formed by a variety of genetically unrelated proteins that share the same folding pattern (—-pleated sheets). The characteristics of the three most common forms of amyloidosis are given in Table 58-. Although amyloidosis is the most common form of restrictive cardiomyopathy, its prevalence in

Table 58-4 • Left Atrial (LA) Pressure Estimation by E/E' Ratio

E/E'	LA Pressure
<8	Normal
8–15	Can't Tell
>15	High

the general population is very low (acquired systemic amyloidosis occurs in 1 in 100,000 US person-years).

MYOCARDIAL FIBROSIS occurs due to excessive deposition of collagen fibers in the extracellular matrix. It is often seen in patients with left ventricular hypertrophy due to systemic hypertension and, thus, may be the contributing factor to at least some form of heart failure with the normal LVEF (see below). It also occurs following chest radiation and in late stages of *Trypanosoma cruzi* infection. Frequently, myocardial fibrosis has no apparent cause and is then referred to as being idiopathic.

HYPEROXALURIA is characterized by calcium oxalate deposits in various organs including the myocardium, the kidneys, and the liver.

LYSOSOMAL STORAGE DISORDERS are due to lysosomal enzyme deficiencies that lead to the inability to break down normal cellular constituents. Lysosomal deposits include lipids (as in Gaucher's and Nieman-Picks disease), mucopolysaccharides (as in Hurler's disease), and gangliosides (as in Tay-Sachs disorder). Gaucher's disease is the most common lysosomal storage disease and is characterized by a marked increase in LV wall thickness and stiffness.

HEART FAILURE WITH NORMAL LV EJECTION FRACTION (HFNEF)

Epidemiologic surveys and case-control studies, in both inpatient and outpatient settings, have demonstrated that, at present, about 50% of patients presenting with signs and symptoms of heart failure have a normal or near-normal ejection fraction, no significant valvular disease, and no evidence for hypertrophic or restrictive cardiomyopathy.

Age is the major risk factor for HFNEF; the older the studied population, the higher the prevalence of HFNEF compared to systolic heart failure. With the rapidly aging population, HFNEF is expected to become the dominant form of heart failure in the near future. Other risk factors include female gender, systemic hypertension, LV hypertrophy (LV mass index $>122 \text{ g/m}^2$ in women and $>149 \text{ g/m}^2$ in men), and diabetes mellitus.

Because these individuals present with clinical signs and symptoms of heart failure in the setting of normal or near-normal LV systolic function (LV ejection fraction $\geq 50\%$), normal or small LV diastolic volumes, and no significant valvular heart disease, they are presumed to have diastolic heart failure. However, there is a paucity of data in these individuals on the presence of true LV diastolic dysfunction as defined by abnormal tau and LV stiffness modulus values. Because true LV diastolic dysfunction has not been demonstrated directly in large groups of such patients, some researchers believe that the term *diastolic heart failure* should not be applied to these patients; instead, they propose *heart failure with normal LV ejection fraction* as a more neutral term for this disorder.

Indeed, HFNEF is a syndrome in which the LV filling pressure elevation is only partly explained by an intrinsic LV diastolic dysfunction, because there is often a contribution from an increase in afterload (elevated systemic blood pressure; stiff aortic wall) and/or preload (anemia; renal failure). In one study, the mortality and morbidity of HFNEF was shown to be lower than that of systolic heart failure.

DIAGNOSIS OF DHF

Symptoms and signs of DHF are similar to those of systolic heart failure. Symptoms include fatigue and breathlessness including dyspnea on exertion, orthopnea, and paroxysmal nocturnal dyspnea. On physical exam, one finds pulmonary rales and peripheral edema. Cardiac auscultation may reveal either an S4 gallop (in Grade I LV diastolic dysfunction) or an S3 gallop (in Grades II-IV).

A chest radiograph reveals left atrial enlargement and pulmonary vascular congestion. Electrocardiographic (ECG) findings in NEF-CHF often include signs of left atrial enlargement and left ventricular hypertrophy. In contrast, an ECG in patients with cardiac amyloidosis usually has diminished voltage, as the wall thickening in these cardiomyopathies is due to deposits of electrically inert substances. In fact, the discrepancy between the low QRS voltage on the ECG and the apparent LV hypertrophy (or more precisely, LV wall thickening) on echocardiography is frequently the first diagnostic clue that the patient might have restrictive cardiomyopathy, such as amyloidosis.

Just as in systolic heart failure, a laboratory test for DHF often reveals an elevation of plasma brain natriuretic peptide (BNP). In NEF-CHF, lab tests frequently reveal anemia and some degree of renal insufficiency.

Echocardiography plays the central role in the diagnosis of DHF; it provides information in the following four areas:

1. ESTIMATION OF THE FILLING PRESSURES (e.g., LA pressures by E/E' ratio, pulmonary wedge

pressure by E/Vp, and LV pre-A diastolic pressure by the pulmonary vein AR duration of more than 30 msec compared to mitral A wave). The finding of elevated pressure within 72 hours of presentation helps differentiate DHF from other causes of breathlessness. A serial filling pressure estimation may also be helpful in monitoring therapy in acute setting.

2. DETERMINATION OF LV EJECTION FRACTION. Normal LV ejection fraction excludes systolic dysfunction.
3. DETERMINATION OF MITRAL AND PULMONARY VENOUS FLOW PATTERNS (normal, abnormal relaxation, pseudonormalization, and restrictive filling). A pseudonormal pattern in middle-age and elderly patients may be distinguished from the normal pattern by the presence of $S < D$ in pulmonary vein tracings, diminished E velocity or Vp, and an AR – A wave duration of >30 msec. The filling pattern and the grade of LV diastolic dysfunction may change over time in the same patient; they may worsen as the disease progresses (as has been clearly shown in amyloidosis) or may improve (if it occurs following diuretic therapy and the decrease in filling pressures).
4. CALCULATION OF LA VOLUME. The presence of an increased LA volume in the absence of a chronic volume overload or mitral valve disease is indicative of chronically elevated LA pressures and thus supports the diagnosis of DHF. Conversely, if one is contemplating the diagnosis of a pseudonormal filling pattern (Grade II LV diastolic dysfunction) but finds a normal LA volume, a diagnosis different from DHF should be considered.
5. CALCULATION OF LV VOLUME AND MASS. In both NEF-CHF and restrictive cardiomyopathies, the LV wall thickness is increased and, thus, the calculated LV mass is increased ($>LV$ mass index >122 g/m² in women, and >149 g/m² in men). LV volumes in isolated DHF are normal (end-diastolic volume <97 mL/m²; end-systolic volume is <49 mL/m²).

A tissue biopsy may be required for definitive diagnosis of restrictive cardiomyopathies. An endomyocardial biopsy may often be replaced by a peripheral tissue biopsy, such as fat pad biopsy in amyloidosis.

THERAPY OF DHF

The choice of therapy in DHF is dictated by the general heart failure staging algorithm proposed by the American College of Cardiology and the American Heart Association and applicable to both systolic and diastolic heart failure (Figure 58-9). The ACC/AHA guidelines for the treatment of chronic heart failure in adults were last revised in 2005.

Stage A: At this early stage, individuals have risk factors for the development of LV remodeling and eventual heart failure. The major risk factors for the development of DHF (hypertension, diabetes mellitus, and metabolic syndrome) should be treated according to established guidelines. Thiazide diuretics, beta-blockers, and angiotensin-converting enzyme inhibitors (ACE-I) or angiotensin receptor blockers (ARBs) are beneficial for preventing DHF in many patients with the above risk factors. Disease specific therapy, if available, should be offered to patients with restrictive cardiomyopathy (e.g., appropriate treatment of multiple myeloma in patients with AL type amyloidosis).

Stage B: At this stage, patients have already undergone LV remodeling, which in case of isolated DHF refers to an increase in LV wall thickness and stiffness without chamber dilation. The use of thiazide diuretics, beta-blockers, and angiotensin-converting enzyme inhibitors (ACE-I) or angiotensin receptor blockers (ARBs) prevents further LV remodeling and may even reverse it.

Stage C: It denotes patients with current or past symptoms of DHF. No therapeutic intervention has been shown unequivocally to alter the natural course of DHF once the symptoms develop. This is in marked contrast with systolic heart failure, where multiple medical and electrical therapies have been shown to prolong life. In addition to the continuation of measures taken at Stages A and B, one may use diuretics to control fluid overload. In patients with atrial fibrillation and rapid ventricular response, the ventricular rate should be controlled with atrioventricular nodal blocking agents according to appropriate guidelines.

Coronary revascularization may be considered if demonstrable myocardial ischemia is thought to contribute to symptoms of DHF.

Stage D: These patients have symptoms at rest despite maximal medical therapy. There are no clinical trials data specifically addressing the issue of therapy for DHF at this stage. Heart transplant, inotropic supports, LV assist devices, and experimental therapy may be considered.

Suggested Readings

1. Oh JK, Appleton CP, Hatle LK, Nishimura RA, Seward JB, Tajik AJ. The noninvasive assessment of left ventricular diastolic function with two-dimensional and Doppler echocardiography. *J Am Soc Echocardiogr.* 1997;10(3):246–270.
2. Maurer MS, Spevack D, Burkhoff D, Kronzon I. Diastolic dysfunction: Can it be diagnosed by Doppler echocardiography? *J Am Coll Cardiol.* 2004;44(8):1543–1549.
3. Vasan RS, Levy D. Defining diastolic heart failure: A call for standardized diagnostic criteria. *Circulation.* 2000;101:2118–2121.
4. Paulus JW, Tschöpe C, Sanderson JE, et al. How to diagnose diastolic heart failure: A consensus statement on the diagnosis of heart failure with normal left ventricular ejection fraction by the Heart Failure and Echocardiography Associations of the European Society of Cardiology. *Eur Heart J.* 2007;28:2539–2550.
5. Nagueh SF, Kopelen HA, Zoghbi WA. Feasibility and accuracy of Doppler echocardiographic estimation of pulmonary artery occlusive pressure in the intensive care unit. *Am J Cardiol.* 1995;75:1256–1262.



Author Query

AQ1: Please fill in greek letters/symbols, as they were dropped.

AQ2: Figures have been renumbered as callouts were not in sequence. Please check

AQ3: Regarding “see below,” please be more specific.

AQ4: Regarding “see below,” please be more specific.

AQ5: Please fill in the missing symbol, as it has dropped out.

AQ6: As per our understanding it should be table 58-4.

AQ7: Regarding “see below,” please be more specific.